



Feasibility Study of Tantalum Markers for the Treatment of Ocular Melanoma with Cyberknife Stereotactic Radiotherapy

Anna Stefania Martinotti, Irene Redaelli, Achille Bergantin, Paolo Bonfanti, Chiara Spadavecchia

Cyberknife Center, Centro Diagnostico Italiano, Milan

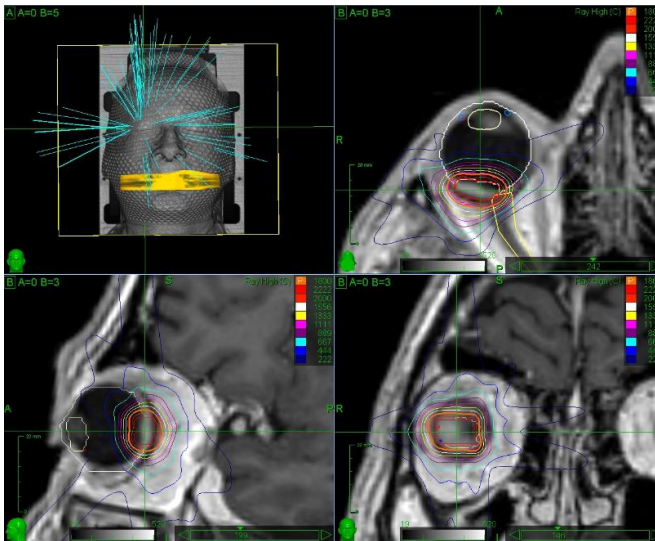


Frontiers of Radiosurgery

**OCTOBER 24 & 25, 2019
MILANO, ITALY**

General information

- ✓ 34 patients suffering from ocular melanoma treated with Cyberknife from April 2014 to May 2019
- ✓ CT simulation with thermoplastic mask, co-registered with orbit MRI with gadolinium (T1 and T2)
- ✓ Prescription dose 54/60 Gy in 3 fractions, 80% isodose level
- ✓ GTV contoured on the MRI, added 2,5 mm in all directions for the PTV delineation
- ✓ Repeated CT scan, co-registered with simulation CT, before every treatment session

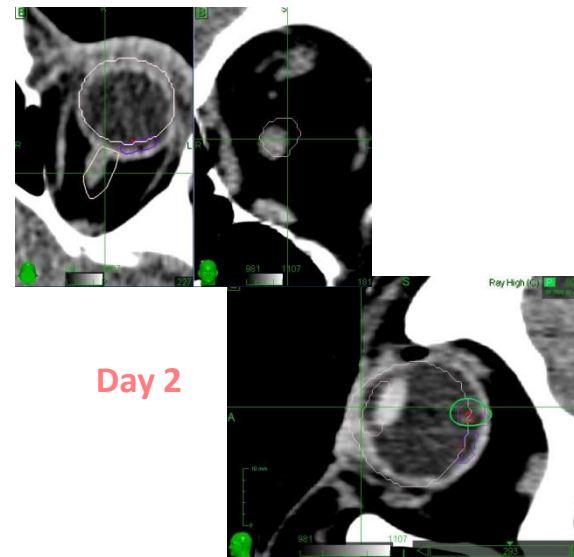
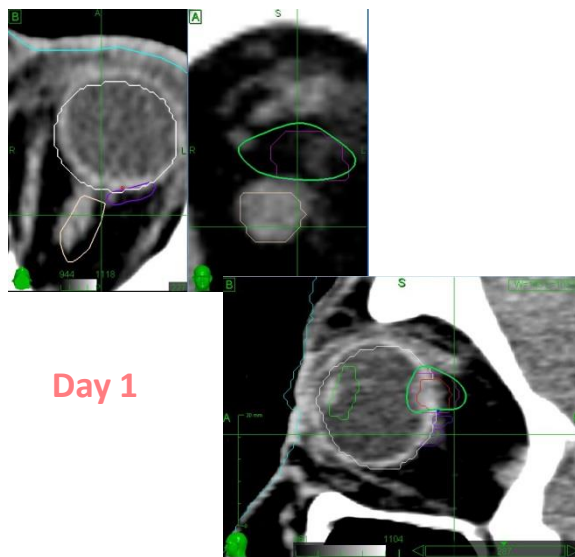


Three different approaches for eye positioning and tracking

First approach: retrobulbar anaesthesia

- 8 patients treated (24% of the total)
- Stabilization of the eye ~ 20 min prior to CT
- Tracking based on the bony anatomy of the skull (6D skull)

After the anaesthesia, the **eyeball** has the tendency to displace from its original position in an unpredictable way, verified by means of the pre-treatment CT scan.



In one case it was necessary to replan on a new CT (30 Gy in single fraction).

Repeated retrobulbar anaesthesia is considered as too invasive in a fractionated scheme.

Second approach: no anaesthesia, eyelids closed

- Eye closed while resting with a bandage on it
- Tracking based on the bony anatomy of the skull (6D skull)

From the co-registration between the simulation and the pre-treatment CT, rotations of the eye were detected in a small number of patients, while translations were always negligible.

All the x (CC), y (LL) and z (AP) displacements of the *lens/optic nerve insertion* are used as surrogate markers of the lesion's position.

x (mm)	y (mm)	z (mm)
1,0 ± 0,6	1,1 ± 0,5	0,8 ± 0,3



Our 2.5 mm margin from GTV to PTV is appropriate.

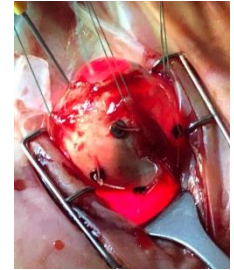
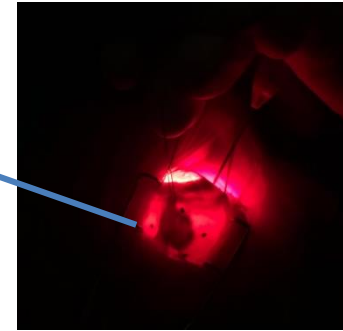
Despite being a minimally invasive technique, its value is limited by the fact that the intrafraction movement of the eye isn't monitored during treatment .

The treatment sessions are too long (around 45 min) to use an eye fixation device.

The new approach: use of Tantalum markers

- Eye closed while resting with a bandage on it
- Fiducia Tracking based on tantalum markers, sutured to the sclera around the tumor

- diameter 2,5 mm, thickness 0,17 mm
- nonmagnetic
- highly resistant to chemical attack
- very little adverse biological response



Phantom measurements with different configurations: anthropomorphic phantom, Ball Cube II, Mini Ball Cube

The crucial parameter is the distance between the treated target and the alignment center. If we use the skull to track the eye (~ 10 cm apart), we are introducing another source of error.

Critical issues for patients:

- ✓ Artifacts in CT and MR
- ✓ Distance between fiducials (< 18 mm)



Can we really think of reducing margins???

Conclusions

The use of radiopaque markers implanted near the lesion seems to be the optimal choice, cause it guarantees a real-time tracking of the eye movement.

There are still some open issues for the clinical implementation of this technique.

The tracking accuracy with markers will be evaluated for the first cases, simulating the patient set-up and alignment on the treatment machine.

The improvement of treatment accuracy could lead to a potential toxicity reduction.



A special thanks to

MD Marco Pellegrini

*Eye Clinic, Ospedale Luigi Sacco, Università degli Studi di Milano,
Milan*