



KOÇ UNIVERSITY
HOSPITAL
GAMMA KNIFE CENTER



Gamma Knife anterior capsulotomy for treatment resistant obsessive compulsive disorder

Selcuk Peker

Koç University School of Medicine
Department of Neurosurgery
Istanbul, Turkey

OCD

Obsessive Compulsive Disorder

- Characterized by the persistent intrusion of repetitive, unwanted thoughts.
- May be accompanied by compulsive actions, such as hand washing.
- The individual cannot voluntarily prevent these thoughts or actions, which interfere with normal functioning.
- Prevalence 1-2%
- 10-30 % do not respond medical treatments

OCD

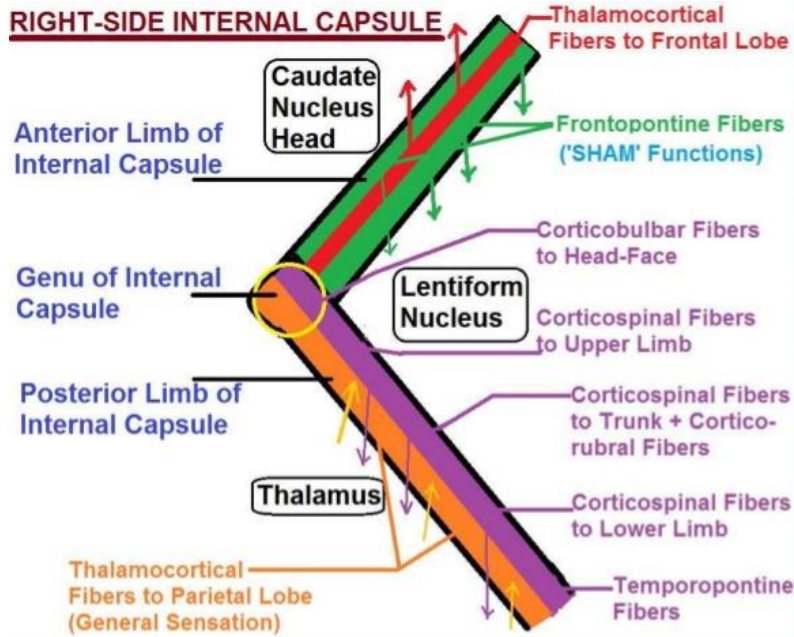
Obsessive Compulsive Disorder

Medical treatments

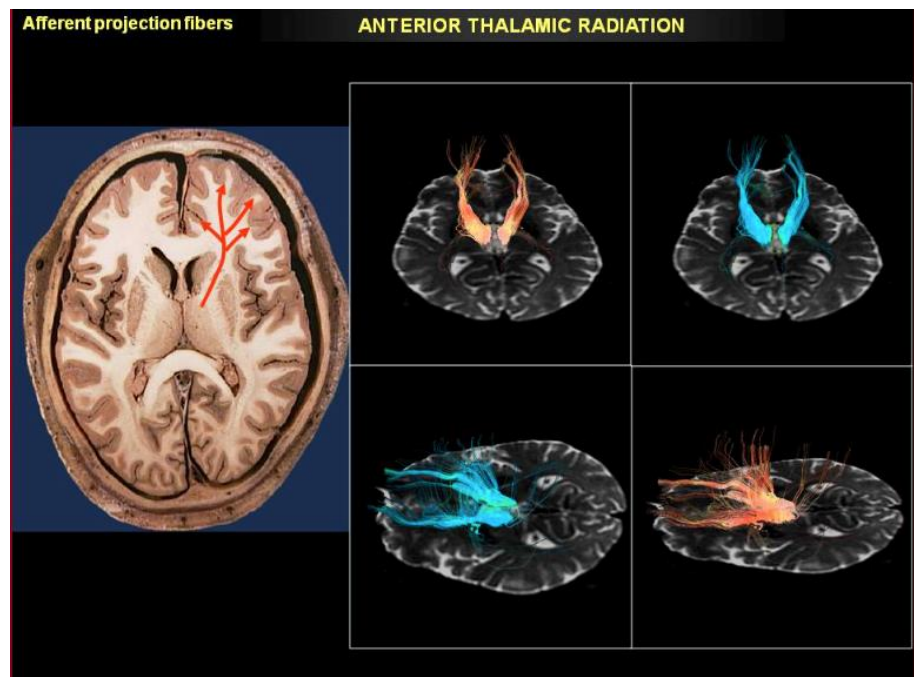
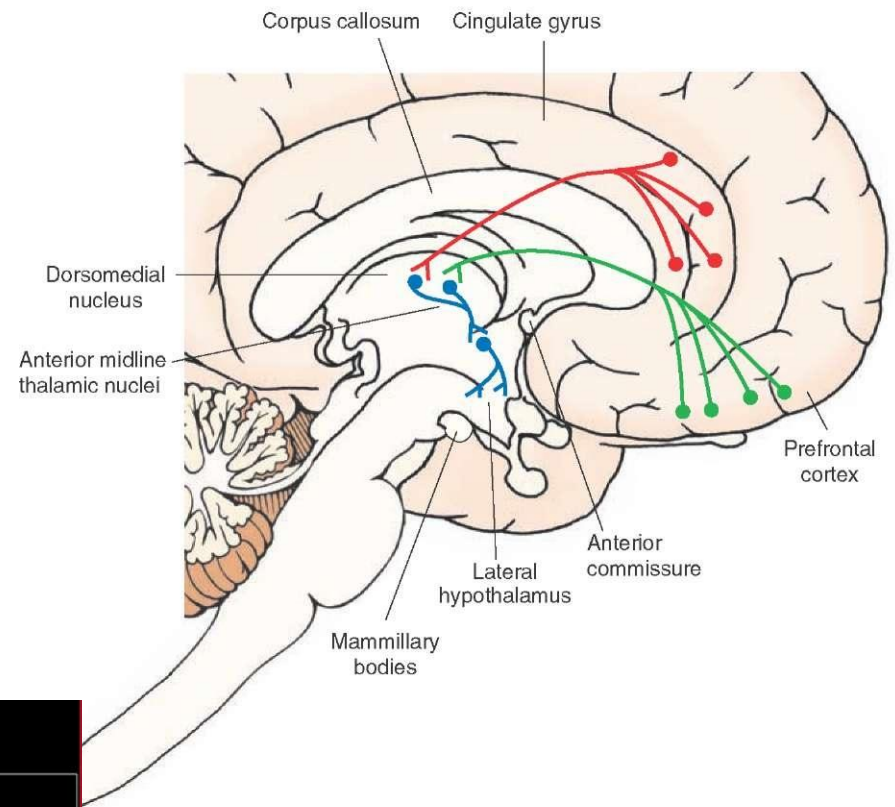
- Cognitive-behavioral therapy
- Pharmacotherapy
 - SSRI (selective serotonin reuptake inhibitors)
 - Neuroleptics
 - Benzodiazepines

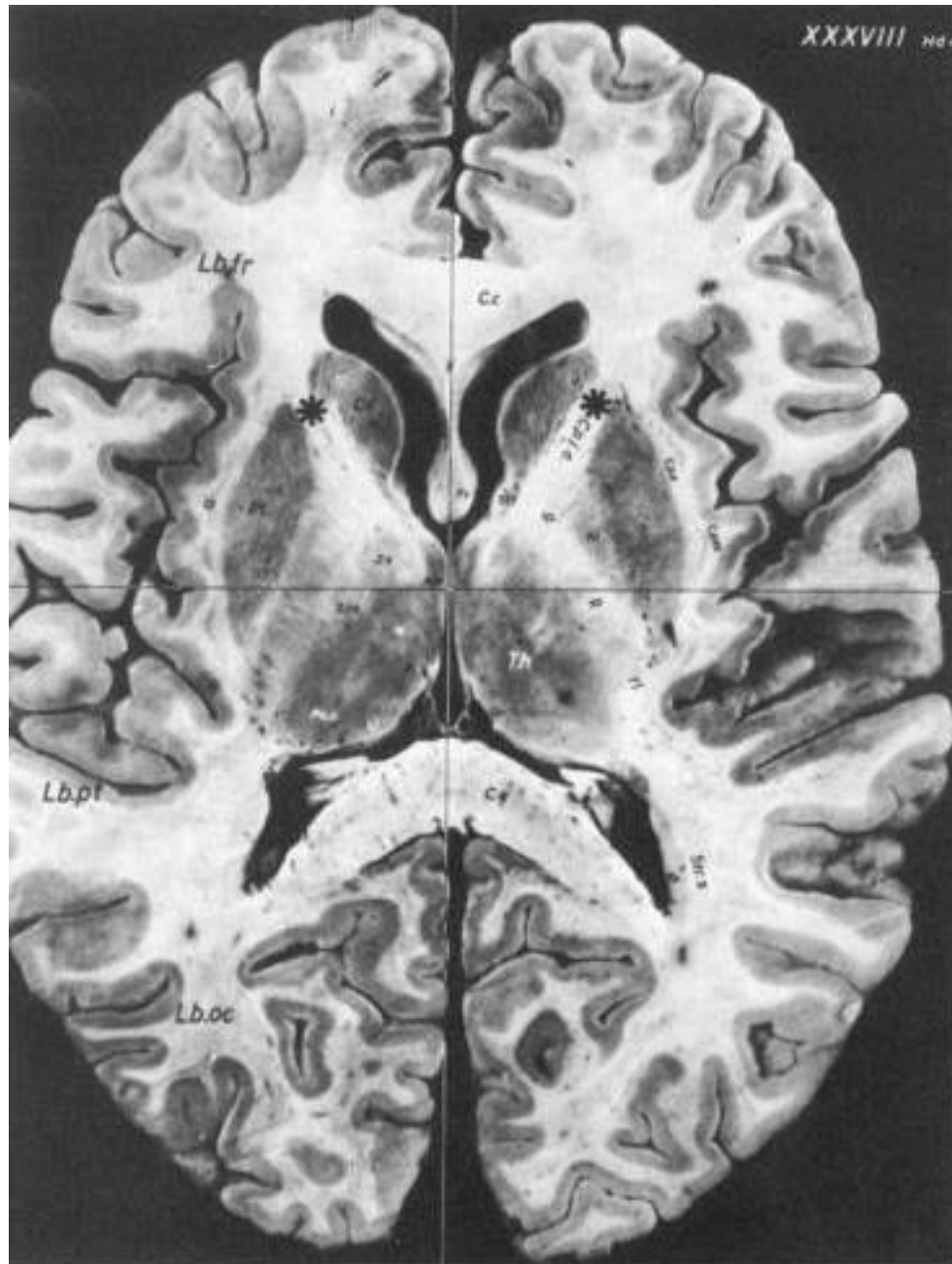
Indications for surgery in OCD

- Severe OCD with Y-BOCS > 25
- No intracranial structural anomalies
- At least 5 years of medical therapies and behavioral therapy
- Older than 20 years old



Internal Capsule – Tracts





Our Series

Demographics

- 2007-2016
- 21 pts (11 males and 10 females)
- Median age 32 (20-51)
- Median Y-BOCS Score 37 (25-40)
- Median duration of disease 15 years (6-24)

Our Series

PreGK

- All patients had medical treatment, CBT
- 3 patients had ECT
- Had report from their physicians
- Psychiatrist and Psychologist evaluation

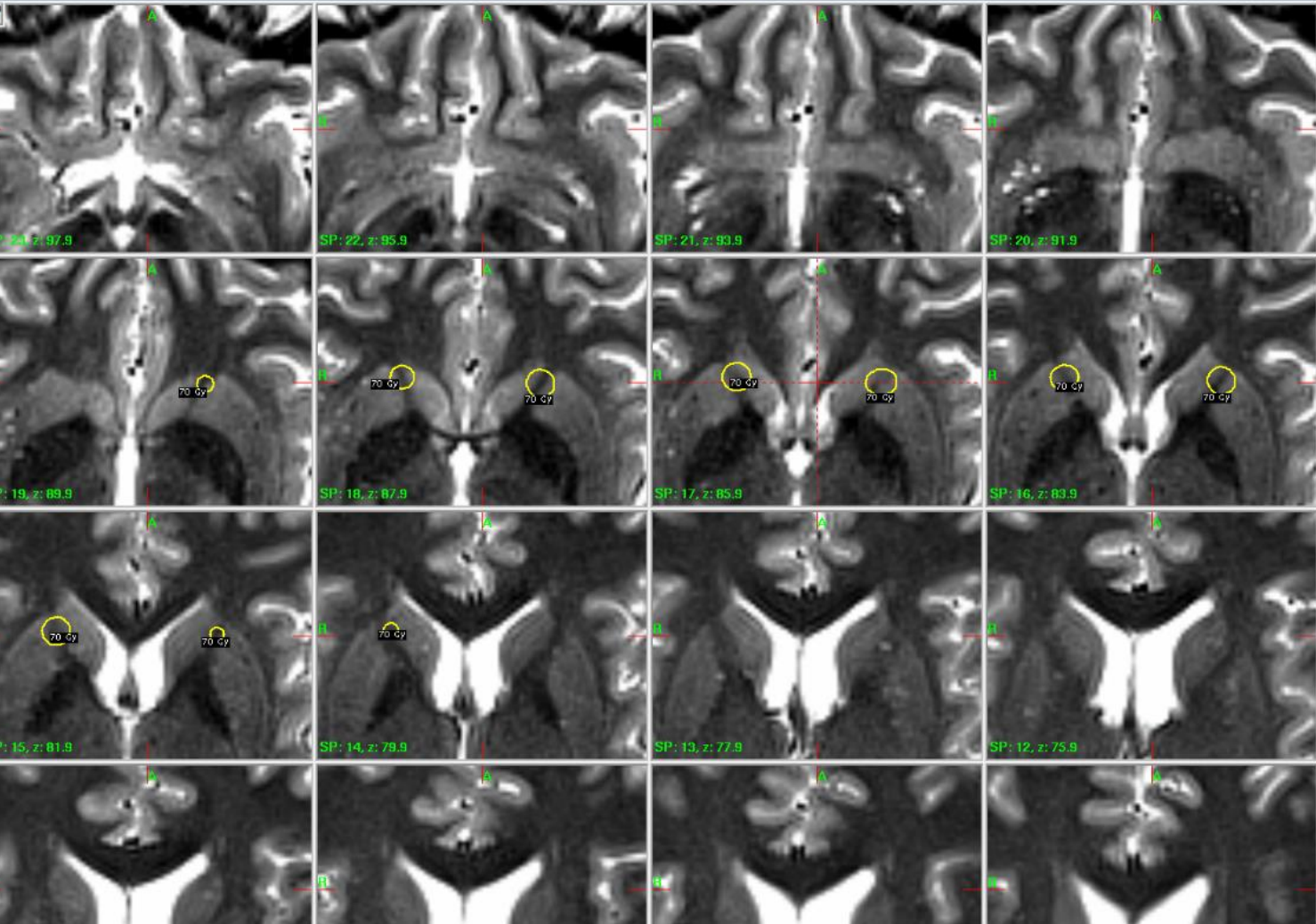
Our Series Treatment

- 2 pts Gamma knife Model 4C
- 19 pts Gamma knife Perfexion
- Single 4 mm shot bilaterally 2 pts
- Double 4 mm shots bilaterally 19 pts

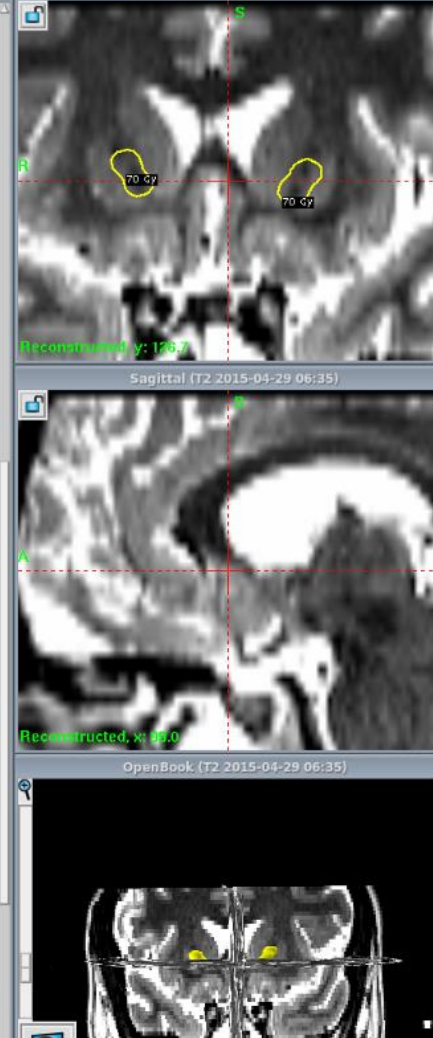
Our Series Treatment

- Shot distance
 - R side 4,9 mm (4,0-5,5 mm)
 - L side 4,7 mm (3,8-5,2 mm)
- Total Volume 50% 412 mm³ (179-484 mm³)
 - Right 212 mm³ (89-245 mm³)
 - Left 200 mm³ (90-242 mm³)
- Volume 50 Gy 721 mm³ (324-841 mm³)
- Volume 12 Gy 7 cc (3-9 cc)
- Treatment time 212 min (127-264 min)

Axial (T2 2015-04-29 06:35)



Coronal (T2 2015-04-29 06:35)



Our Series

Treatment

- Median maximum dose 140 Gy (140-150 Gy)
- Median follow-up 52 mo (34-142 mo)

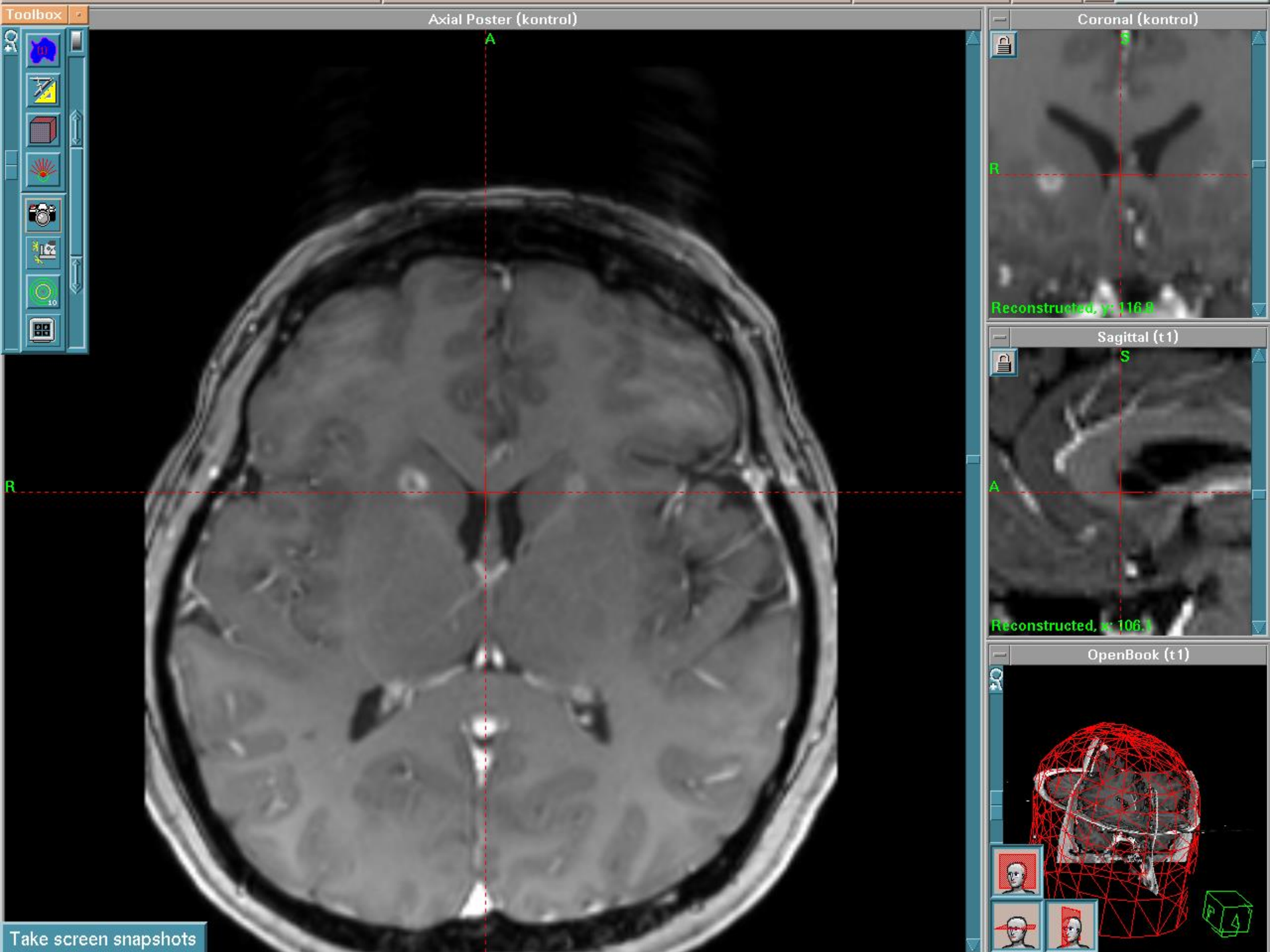
Evaluation of the results

- >35% decrease on Y-BOCS Response
- Y-BOCS is 8> Remission
 - Christmas et al 2005 8>
 - Pallanti et al 2006 16>

Our Series

Results

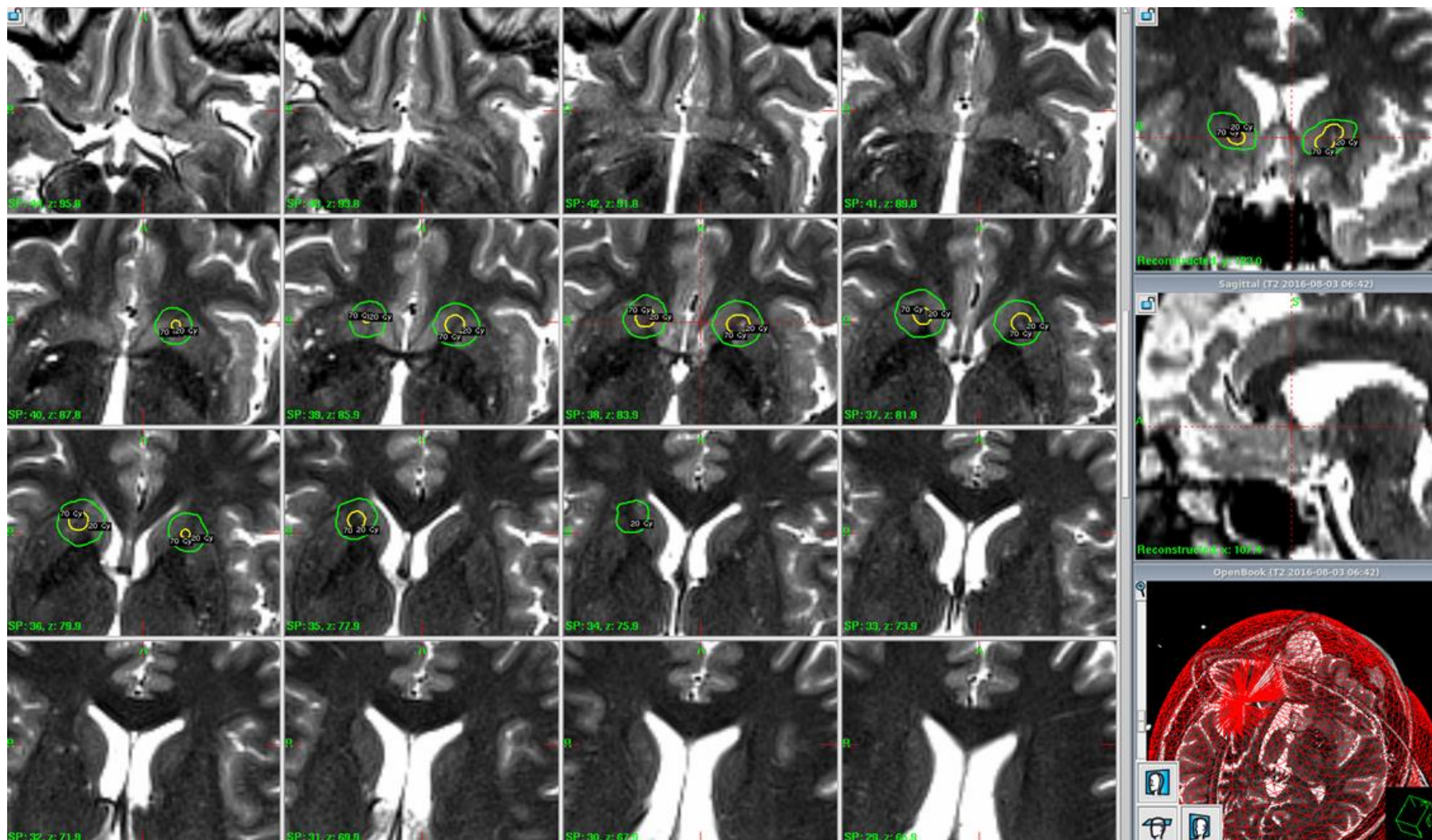
- Y-BOCS score median 16 (0-32)
- 15 pts (71%) clinical improvement
 - 4 pt remission (19%)
 - 6 pts significant improvement
 - 5 pt mild improvement
- 6 pts no improvement
- Clinical or radiological side effects in 2 pts

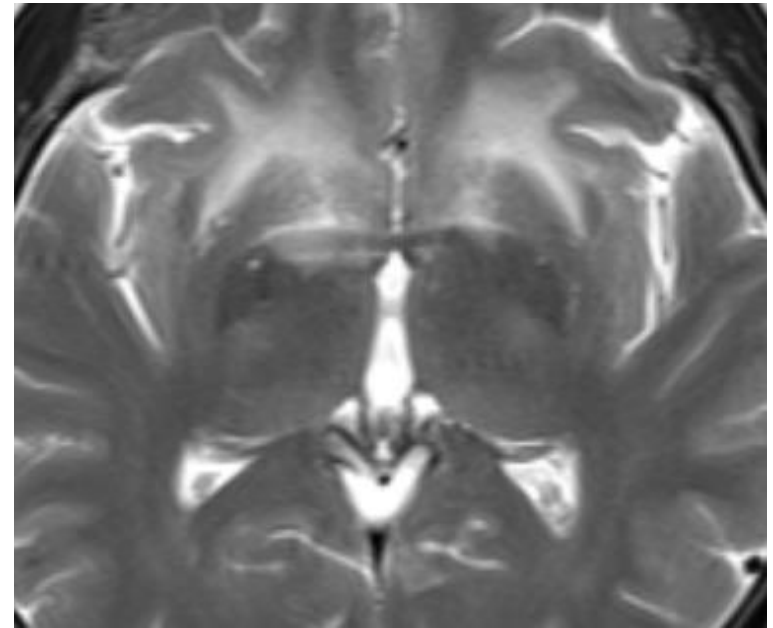
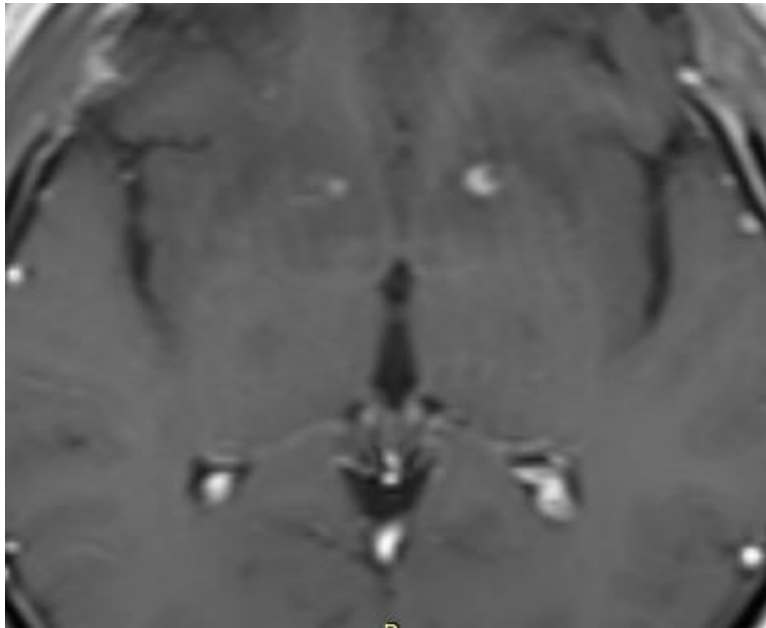


27/M

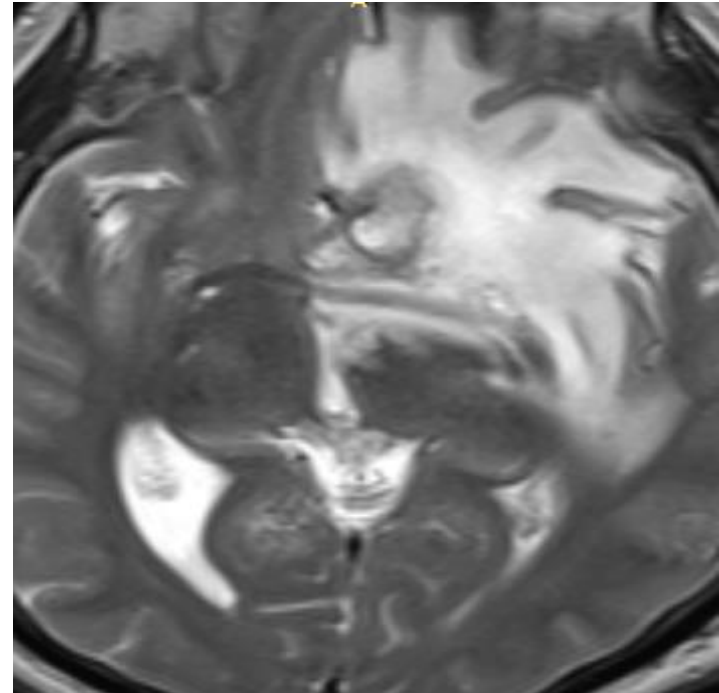
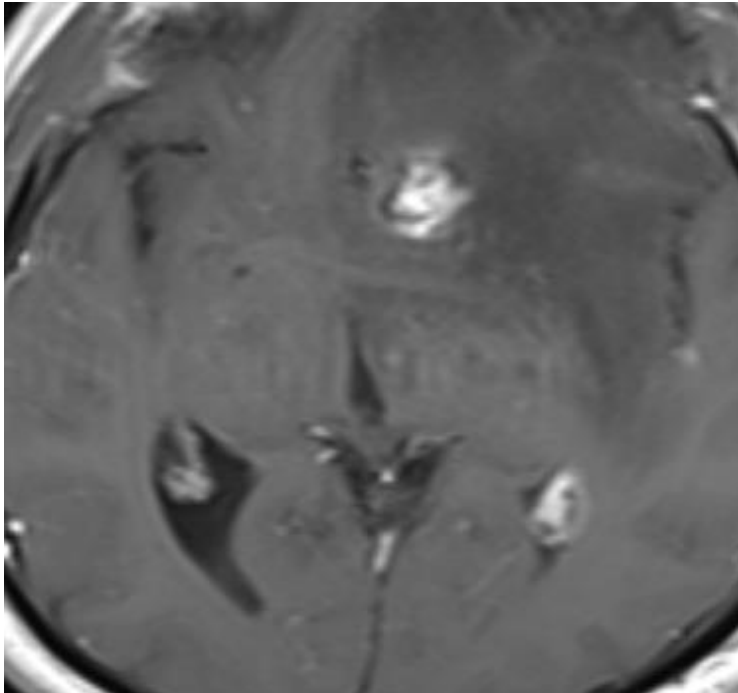
5 Years history of OCD

Y-BOCS 34





Follow-up 1 year



Follow-up 3 years
Headache
Y-BOCS 7
Dexamethasone

Results on different complaints

- Obsessions
- Compulsions
- Depression

NO DIFFERENCE

Radiocapsulotomy Features

- No opening of the skull
- No complications related to surgery
- Improvements are seen after a period of time
- Adverse Radiation Effect (ARE) risk is low

Thank you
peker@selcukpeker.com